

A Rare Paediatric Case Report of Neglected Traumatic Posterior Hip Dislocation

L SABARI VAASAN¹, K SANTHOSH KUMAR², S DEVI PRASAD³, SURAJ J BABAR⁴, J KEVIN DHAS⁵

(CC) BY-NC-ND

ABSTRACT

Traumatic posterior hip dislocation in paediatric age group is a rare but potentially debilitating condition, particularly when neglected. The delay in seeking medical care frequently leads to missed diagnosis, which can lead to an array of future complications. Hence, timely intervention is crucial in treating neglected traumatic hip dislocations in children to prevent complications like avascular necrosis of femoral head, sciatic nerve injury and early degenerative arthritis. Various treatment options exist, ranging from closed reduction and hip spica application to surgical interventions like open reductions and osteotomies. The primary goal of any treatment modality in hip dislocation is to achieve concentric reduction and preventing the possible associated complications. Additionally, there is limited research evaluating the outcomes of closed reduction in neglected traumatic posterior hip dislocations specifically in children. The present case report aims to address this gap by presenting a case of a six-year-old female child with a neglected posterior hip dislocation following a fall from tree six weeks prior, which was managed with continuous traction followed by closed reduction and hip spica cast application. The serial follow-up of the child showed satisfactory clinical outcome as evidenced by improved hip range of motion and normal gait. The successful outcome supports the effectiveness of this approach in managing neglected traumatic hip dislocations in children. This case also emphasises that there should be attempts of closed reduction in all neglected paediatric hip dislocations, followed by hip spica application, before undertaking any surgical interventions, even if they present after six weeks.

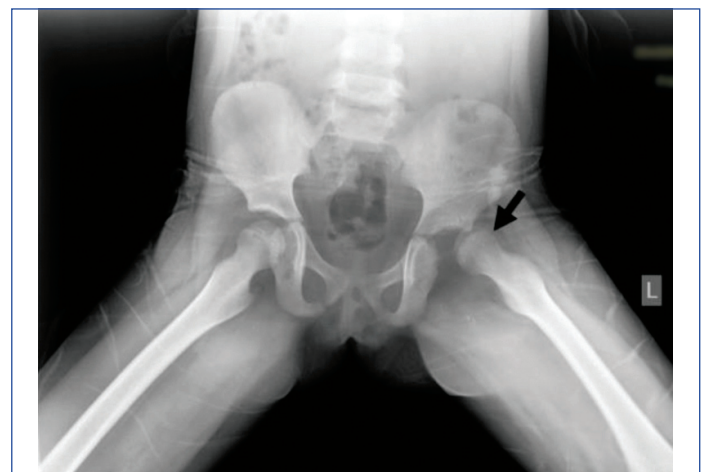Keywords: Avascular necrosis, Closed reduction, Hip spica

CASE REPORT

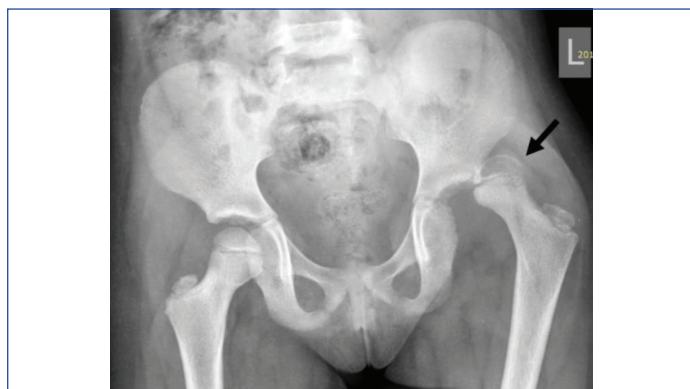A six-year-old female child presented to the Outpatient Department (OPD) with complaints of pain in the left hip associated with difficulty in walking for six weeks following an injury to the left hip due to a fall from a tree (5 feet tall). The child was taken to a local hospital immediately, where a traumatic posterior dislocation of the left hip was identified during initial investigations. Although her parents were advised to undergo closed reduction under general anaesthesia, her parents did not pursue the procedure and native bandaging was applied for six weeks. Six weeks later, the child presented to the hospital with the complaints of persistence of pain and difficulty in walking.

On general examination, the child was moderately built and nourished. There was no evidence of ligamentous laxity and no significant findings were noted during the systemic examination. On local examination, the left hip was found to be flexed, adducted and internally rotated, with apparent limb shortening, posterior joint line tenderness and a hard globular mass palpable in the gluteal region, indicative of a posterior hip dislocation. Anteroposterior (AP) and frog-leg lateral views of the hip were taken to confirm the diagnosis [Table/Fig-1,2]. A Computed Tomography (CT) scan was

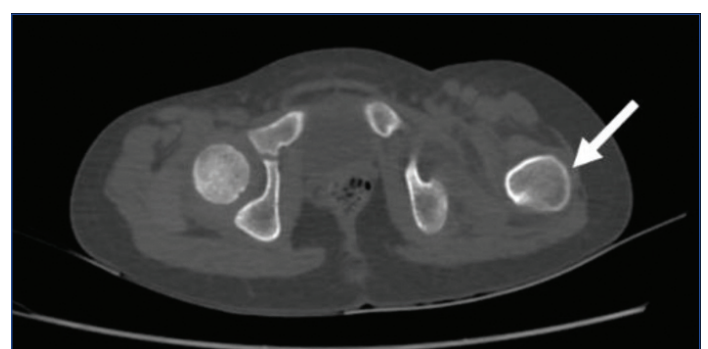
also performed to rule out other associated bony injuries [Table/Fig-3]. An Magnetic Resonance Imaging (MRI) of the hip joint was also done to look for any signs of avascular necrosis [Table/Fig-4] due to the delayed presentation, which revealed pericapsular haematoma.



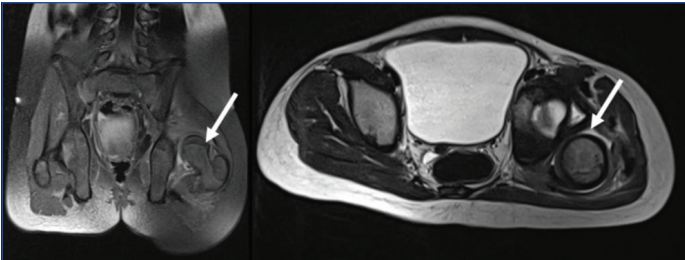
[Table/Fig-2]: Frog leg lateral X-ray of pelvis shows a posterior dislocation of the left hip (Black arrow).



[Table/Fig-1]: The AP radiograph of the pelvis shows a posterior dislocation of the left hip (Black arrow).

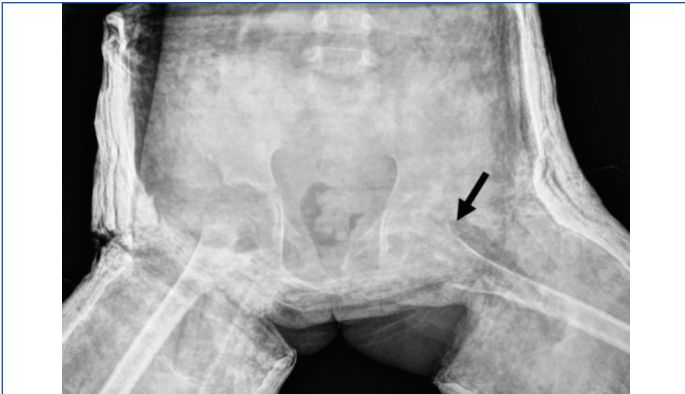


[Table/Fig-3]: CT scan shows posterior dislocation of the left hip (white arrow) with no associated fractures.

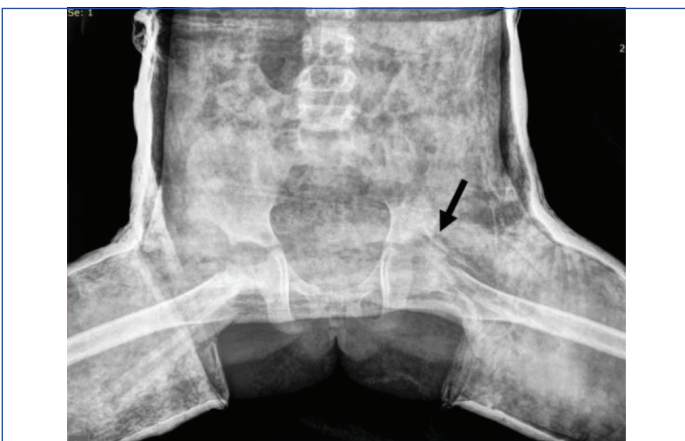

[Table/Fig-4]: MRI scan shows posterior dislocation of the left hip with pericapsular haematoma (as indicated by the white arrow).

The patient was then placed on continuous bilateral skin traction for six days, during which serial X-rays were taken every two days to monitor the level of the femoral head and to plan for subsequent closed reduction under anaesthesia. The patient underwent the procedure on day seven after adequate muscle relaxation was achieved by continuous skin traction. Under fluoroscopic guidance, concentric closed reduction was successfully achieved. The hip was found to be stable in 90 degrees of flexion, 70 degrees of abduction and 30 degrees of external rotation. Furthermore, the hip was immobilised with hip spica cast. The reduction was deemed stable and concentric following hip spica application [Table/Fig-5,6].



[Table/Fig-5]: Immediate postoperative frog leg AP X-ray showing concentric reduction of left hip joint (black arrow).

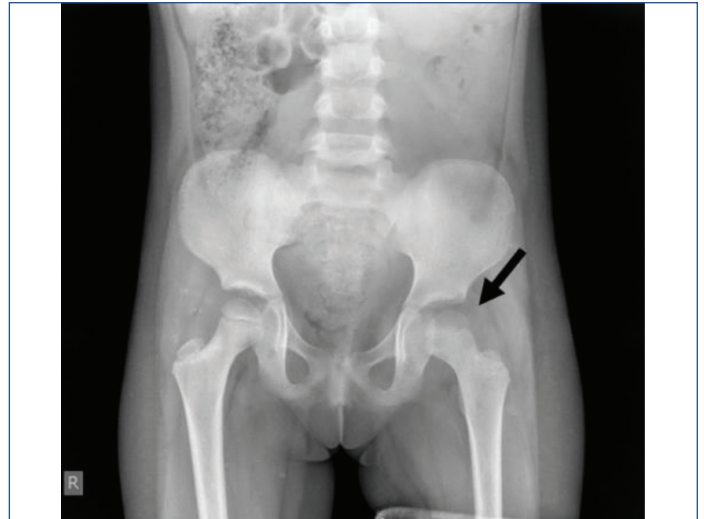


[Table/Fig-6]: Immediate postoperative frog leg lateral view X-ray showing concentric reduction of the left hip joint (black arrow).

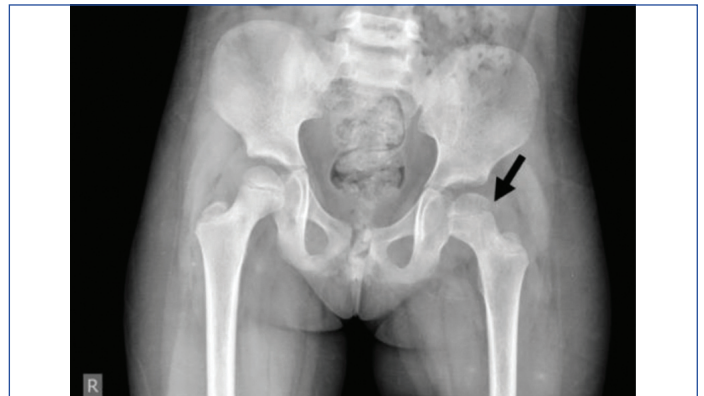
The intraoperative and immediate postoperative periods were uneventful. Postoperatively, the patient was managed with a hip spica cast for four weeks. The patient was followed-up every month and X-rays were taken during each visit [Table/Fig-7,8], which showed satisfactory results. The patient also gained a satisfactory range of motion the hip joint and no limb length discrepancy was noted [Table/Fig-9a,b,10].

DISCUSSION

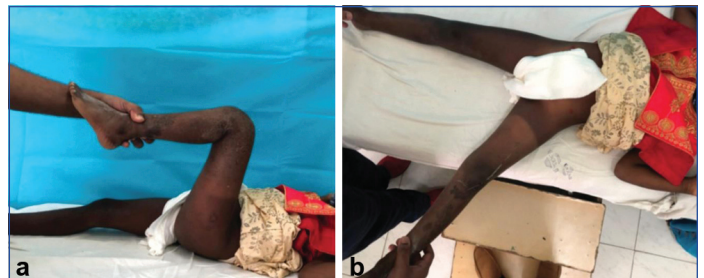In children, traumatic dislocation of the hip joint, especially posterior dislocation, is a rare injury that can be debilitating. Despite its infrequency, it poses significant challenges in management,



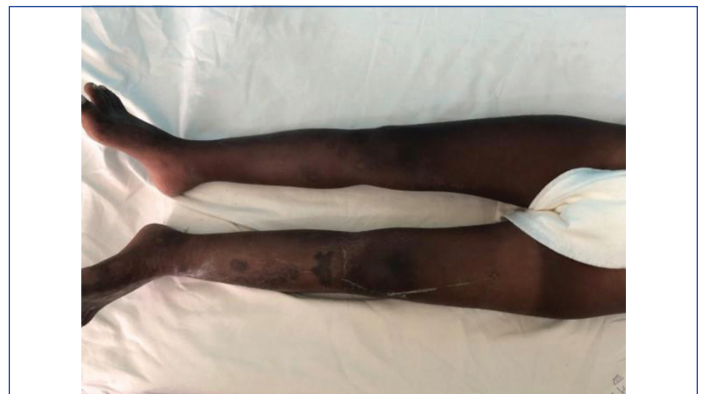[Table/Fig-7]: Six-week-old postoperative AP X-ray shows maintenance of concentric reduction of the left hip joint (black arrow).



[Table/Fig-8]: Three months postoperative AP X-ray shows maintenance of concentric reduction of the left hip joint (black arrow).



[Table/Fig-9a,b]: Three months clinical follow-up picture shows good hip range of motion.



[Table/Fig-10]: Three months clinical follow-up picture shows no limb length discrepancy.

especially when neglected [1,2]. In low- to middle-income countries, where delayed presentation and native treatments are common, neglected cases are more prevalent. The delay in seeking medical care frequently leads to missed diagnosis, which further complicates the condition, particularly when accompanied by multiple injuries or

associated femur fractures [3]. It is essential to intervene promptly to avoid serious complications like avascular necrosis of the femoral head and coxa magna. Another complication is sciatic nerve injury, with an incidence of sciatic nerve injuries differs from 5 to 20%. Redislocation is also a main complication [4], which may cause proximal physical damage it may lead to leg length discrepancy [5]. However, the optimal management of neglected traumatic hip dislocations remains a subject of debate [6].

While various treatment options exist, ranging from closed reduction to surgical interventions, there is a lack of consensus on the ideal approach [7]. The present case report presents a case of traumatic posterior hip dislocation in a six-year-old female child from India. The neglected nature of the dislocation shows the challenges commonly encountered in resource-limited settings like India, emphasising the importance of early diagnosis and intervention to prevent long-term complications.

The mechanism of injury leading to hip dislocation varies across age groups. Younger children often experience dislocations from low-energy traumas due to ligamentous laxity, contrasting with older children who may sustain dislocations from forceful injuries [8]. This variability in injury mechanisms emphasises the need for tailored management strategies based on patient demographics and injury characteristics.

In the present case, a neglected traumatic posterior hip dislocation raises concerns for early complications such as associated fractures and potential neurovascular lesions. The risk of late complications, including avascular necrosis and degenerative arthritis, is heightened due to the delay in joint reduction. Factors associated with worse prognosis, such as delayed reduction exceeding six hours and the presence of intra-articular injuries, highlight the importance of timely intervention to mitigate long-term sequelae [6].

In the current report, the diagnosis of posterior hip dislocation was confirmed based on physical examination findings, including typical hip positioning with flexion, adduction, internal rotation, limb shortening and posterior joint line tenderness [9]. These clinical features align with the classic deformity described in the literature for diagnosing posterior dislocations. This consistency emphasises the reliability of recognising specific physical signs to accurately identify posterior hip dislocations across different clinical settings accurately.

In the present case, the chosen treatment approach of closed reduction under general anaesthesia, followed by hip spica cast application, aligns with standard practice guidelines aiming to achieve stable reduction while minimising surgical intervention [10]. In a similar reported done by Dewanto RR et al., it was found that these cases can be managed by closed or open reduction [5]. In addition, repetitive attempts at closed reduction to be avoided to prevent complications [11].

The differential diagnosis for traumatic hip dislocations includes femoral fractures, acetabular fractures and pelvic fractures, which should be considered based on clinical presentation and imaging findings [11]. Treatment approaches should prioritise achieving anatomical reduction while minimising complications, with close monitoring for signs of avascular necrosis and sciatic nerve injury.

Thus, the present case report highlights the challenges and management strategies associated with traumatic hip dislocations in children, emphasising the importance of early diagnosis, timely intervention and appropriate management to achieve favourable outcomes and prevent long-term complications.

CONCLUSION(S)

Though rare, neglected dislocation of hip is a serious condition and should be treated as early as possible to prevent avascular necrosis of head of femur. The present case report showcases the efficacy of continuous traction followed by closed reduction and hip spica casting in managing neglected posterior hip dislocations in children. It also highlights the importance of timely intervention in paediatric hip dislocation to avoid the need for any surgical intervention and potential complications, as mentioned above.

REFERENCES

- [1] Banskota AK, Spiegel DA, Shrestha S, Shrestha OP, Rajbhandary T. Open reduction for neglected traumatic hip dislocation in children and adolescents. *J Pediatr Orthop*. 2007;27(2):187-91. Doi: 10.1097/BPO.0b013e31802c547e. PMID: 17314644.
- [2] Floyd A. Traumatic dislocation of the hip in a child: A case report. *S Afr Med J*. 1984;65(23):935-37. PMID: 6729638.
- [3] Pal CP, Kumar D, Sadana A, Dinkar KS. Neglected posterior dislocation of hip in children - a case report. *J Orthop Case Rep*. 2014;4(2):21-24. Doi: 10.13107/jocr.2250-0685.161. PMID: 27298953; PMCID: PMC4719367.
- [4] Clausen JD, Winkelmann M, Macke C, Mommsen P, Krettek C, Brand S. A rare case of a traumatic posterior hip dislocation in a 3-year-old boy: A case report and review of the literature. *Case Rep Orthop*. 2020;2020:7560392. Doi: 10.1155/2020/7560392. PMID: 32231831; PMCID: PMC7085349.
- [5] Dewanto RR, Bintaryo YS, Santy JE. Neglected traumatic posterior dislocation of hip in children: Report on 2 cases. *Orthopaedic J Sports Med*. 2020;8(5_suppl5):2325967120S00041.
- [6] Kutty S, Thornes B, Curtin WA, Gilmore MF. Traumatic posterior dislocation of hip in children. *Pediatr Emerg Care*. 2001;17(1):32-35.
- [7] Brandão GF, Américo LR, Soares CBG, Faria RGC, Teixeira LEM. Traumatic posterior dislocation of the hip in children: Report on five cases. *Rev Bras Ortop (Engl Ed)*. 2010;45(2):196-99.
- [8] Herrera-Soto JA, Price CT. Traumatic hip dislocations in children and adolescents: Pitfalls and complications. *J Am Acad Orthop Surg*. 2009;17(1):15-21. PMID: 19136423. Doi: 10.5435/00124635-200901000-00003.
- [9] Archer JE, Balakumar B, Odeh A, Bache CE, Dimitriou R. Traumatic hip dislocation in the paediatric population: A case series from a specialist centre. *Injury*. 2021;52(12):3660-65. Doi: 10.1016/j.injury.2021.04.010. Epub 2021 Apr 7. PMID: 33865607.
- [10] Nagda T, Dhamele J. Closed reduction, arthrogram and spica application for DDH. *Indian J Orthop*. 2021;55:1602-04. Available from: <https://doi.org/10.1007/s43465-021-00542-y>.
- [11] Pai VS, Kumar B. Management of unreduced traumatic posterior dislocation of the hip: Heavy traction and abduction method. *Injury*. 1990;21(4):225-27. Available from: [https://doi.org/10.1016/0020-1383\(90\)90008-l](https://doi.org/10.1016/0020-1383(90)90008-l).

PARTICULARS OF CONTRIBUTORS:

1. Associate Professor, Department of Orthopaedics, SRM Medical College and Hospital, Chengalpattu, Tamil Nadu, India.
2. Postgraduate Student, Department of Orthopaedics, SRM Medical College and Hospital, Chengalpattu, Tamil Nadu, India.
3. Professor, Department of Orthopaedics, SRM Medical College and Hospital, Chengalpattu, Tamil Nadu, India.
4. Professor, Department of Orthopaedics, SRM Medical College and Hospital, Chengalpattu, Tamil Nadu, India.
5. Assistant Professor, Department of Orthopaedics, SRM Medical College and Hospital, Chengalpattu, Tamil Nadu, India.

NAME, ADDRESS, E-MAIL ID OF THE CORRESPONDING AUTHOR:

Dr. L Sabari Vaasan,
Associate Professor, Department of Orthopaedics, SRM Medical College and Hospital, Chengalpattu-603203, Tamil Nadu, India.
E-mail: sabarivl@srmist.edu.in

AUTHOR DECLARATION:

- Financial or Other Competing Interests: None
- Was informed consent obtained from the subjects involved in the study? Yes
- For any images presented appropriate consent has been obtained from the subjects. Yes

PLAGIARISM CHECKING METHODS: [Lain H et al.\]](#)

- Plagiarism X-checker: Jun 28, 2024
- Manual Googling: Aug 31, 2024
- iThenticate Software: Nov 04, 2024 (14%)

ETYMOLOGY: Author Origin

EMENDATIONS: 8

Date of Submission: **Jun 19, 2024**

Date of Peer Review: **Jul 30, 2024**

Date of Acceptance: **Nov 06, 2024**

Date of Publishing: **Dec 01, 2024**